



Critical Factors for Successful Ridge Augmentation Procedure

Raheleh Saeidi Yousefi, Vikram Ravoori, Mitchell Bloom, Stuart Froum, Sang-Choon Cho, Leena Palomo
Ashman Department of Periodontology and Implant Dentistry, New York University, College of Dentistry



INTRODUCTION

Dental implants have been documented to have a high degree of success for single tooth replacement and the restoration of partially and completely edentulous arches. However, horizontal and/or vertical alveolar bone deficiencies constitute a major challenge for implant placement. Many techniques are available today for the experienced surgeon to rebuild lost bone, including autogenous onlay block grafts, allograft block grafts, distraction osteogenesis and guided bone regeneration (GBR). The latter is one of the most well-documented and versatile procedures for regenerating bone in both horizontal and vertical defects, thereby allowing successful implant placement.

The principles of GBR have been developed based on the theory of guided tissue regeneration introduced in the late 1980s and 1990s. The surgical procedure consists of placing an occlusive physical barrier between the connective tissue and the bone defect to prevent the migration of the epithelial and connective tissue cells into the defect and to stabilize the blood clot and graft. This allows the slower migrating osteogenic cells to

proliferate and form new bone, thereby selectively repopulating the wound with osteoblasts prior to the migration of connective tissue and epithelial cells. Scientific evidence in animals and humans has demonstrated that GBR is an effective technique to regenerate lost bone. Despite the fact that GBR is a predictable procedure, complications can arise that may compromise outcomes – membrane exposure, fenestration/dehiscence, infection, graft particle leakage, collapse of the grafted site and excessive bleeding are the most frequently reported complications. Recently, a classification of complications with GBR procedures using non-resorbable membranes was published. Clinical guidelines for the procedures described in this paper, although not evidence-based, were obtained from the experience of the authors over the last 20 years in the treatment of patients at New York University College of Dentistry, Department of Periodontology and Implant Dentistry, with GBR for site development prior to, or simultaneously with, implant placement.

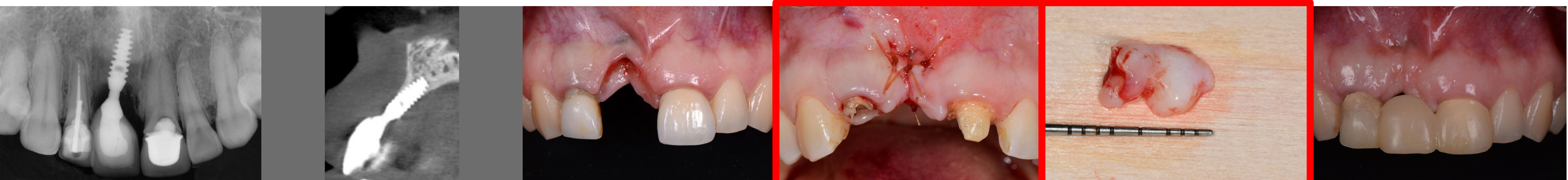
SEQUENCE OF PROCEDURE

- 1. Frenectomy**
Reduce tension after surgery
- 2. Soft tissue graft first**
Evaluate potential of healing
- 3. Releasing incision**
Reduce scar tissue due to very apical incision and single incision
- 4. Horizontal mattress suture**
Allow tension free closure
- 5. CARS & converting bony defect type**
This customized alveolar ridge splitting technique is indicated for treating severely atrophic horizontal ridges that consist of only cortical bone with a reduced blood supply.

CASE REPORT

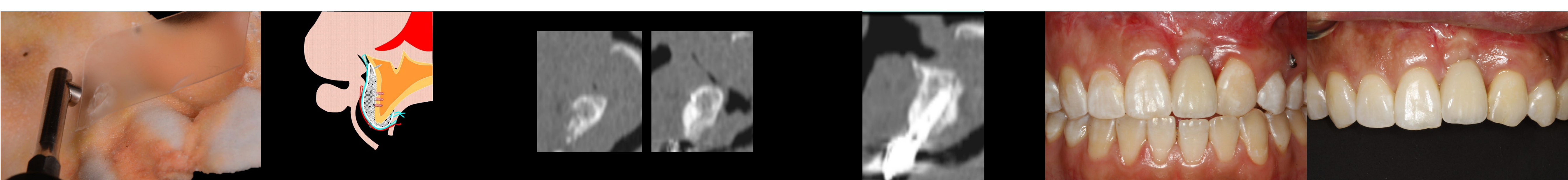
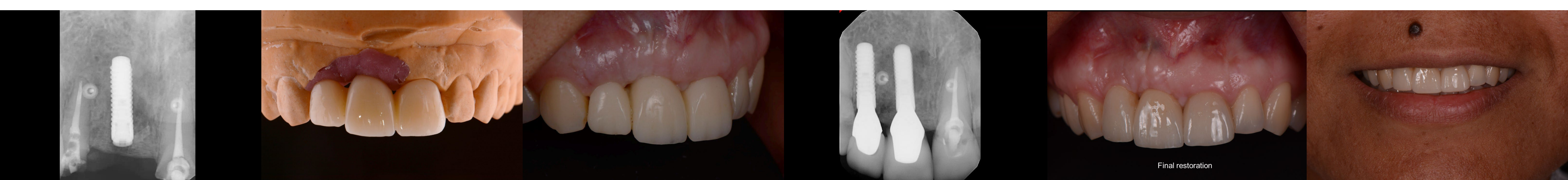
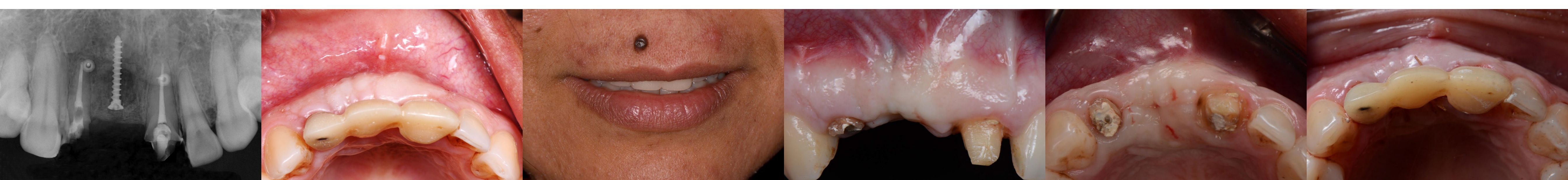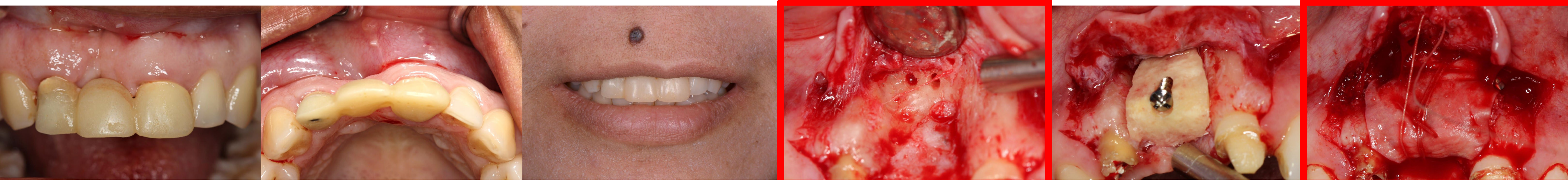1. FRENECTORY

2. SOFT TISSUE GRAFT FIRST

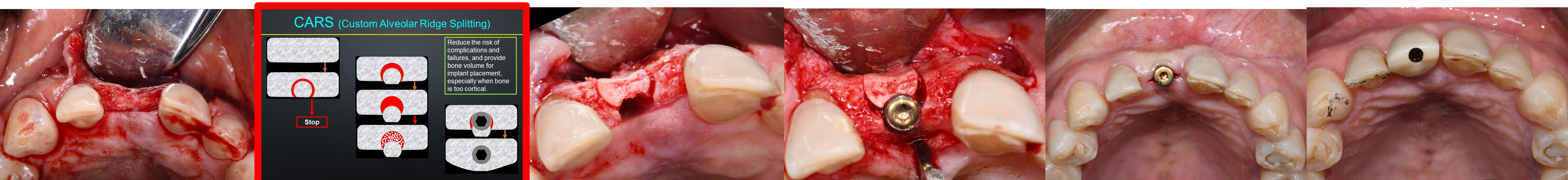


3. RELEASING INCISION

4. HORIZONTAL MATTRESS SUTURE



5. CONVERTING EXTRA-OSSEOUS DEFECT TO INTRAOSSEOUS DEFECT



CONCLUSION

The etiology of GBR complications using resorbable membrane may be multifactorial. Therefore, meticulous surgical and restorative procedures are necessary to reduce the prevalence of complications. Understanding and utilization of proper incision design and flap advancement, releasing incisions, bone decortication, stabilization of the graft and membrane, tension-free primary closure of the flap, and postoperative patient compliance are crucial factors in obtaining predictable outcomes with the GBR technique as described. The Customized Alveolar Ridge Splitting (CARS) technique represent a viable, minimally-invasive augmentation technique for horizontal bone defects. GBR could be considered in combination with CARS to improve ridge contour.

REFERENCES

- Nyman S, Lang NP, Buser D, Bragger U. Bone regeneration adjacent to titanium dental implants using guided tissue regeneration: a report of two cases. *Int J Oral Maxillofac Implants.* 1990 Spring; 5(1): 9-14.
- Buser D, Bragger U, Lang NP, Nyman S. Regeneration and enlargement of jaw bone using guided tissue regeneration. *Clin Oral Implants Res.* 1990;1(1):22-32.
- Jung RE, Glauser R, Schärer P, Hammerle CH, Sailer HF, Weber FE. Effect of rhBMP-2 on guided bone regeneration in humans. *Clin Oral Implants Res.* 2003 Oct; 14 (5): 556-568.
- French D, Ofec R, Levin L. Long term clinical performance of 10 871 dental implants with up to 22 years of follow-up: A cohort study in 4247 patients. *Clin Implant Dent Relat Res.* 2021 Jun;23(3):289-297. doi: 10.1111/cid.12994. Epub 2021 Mar 25. PMID: 33768695; PMCID: PMC8359846.
- Froum SJ, Kadi RO, Wangsrimgkol B, Hengjeerajaras P, Reis N, Yu PYC, Cho SC. The Custom Alveolar Ridge-Splitting (CARS) Technique for Predictable Horizontal Ridge Augmentation in the Atrophic Anterior Maxilla: A Retrospective Case Series Study. *Int J Periodontics Restorative Dent.* 2021 May-Jun;41(3):397-403. doi: 10.11607/prd.5411. PMID: 34076636.